

# Controlled, randomized multicenter study to compare compatibility and safety of ChondroFiller liquid (cell free 2-component collagen gel) with microfracturing of patients with focal cartilage defects of the knee joint

Ulrich Schneider

## ABSTRACT

**Aim:** Verification of the functionality of a newly acellular liquid collagen type-I gel (ChondroFiller liquid) to treat defined small and medium sized cartilage defects of the knee joint. **Methods:** In this prospective randomized study are overall 23 patients included and randomized. Thirteen patients are allocated to the ChondroFiller liquid (CF) and 10 patients to the microfracturing (Mfx) group. All CF patients were operated appropriate, 6 of the 10 patients of the Mfx group refused the allocated surgery. The determination of the effectivity of the single surgery procedure was done by clinical outcome-scores (IKDC) at 3rd, 6th and 12th months and MRI examinations in the CF group (MOCART score) at 4th and 52nd weeks. **Results:** The mean IKDC patient values in the CF-group after 3rd and 6th months were significantly improved from the preoperative values ( $p < 0.05$ ). This improvement remained up to one year follow-up. Based on the high dropout rate in the Mfx-group the clinical data were not analyzed. In the CF-group we could demonstrate a good immediate filling of all treated defects in

the MRI follow-ups. The implant shows a perfect integration to the adjacent cartilage right from the beginning and by time an impressive maturation of the reconstructed cartilage. Adverse events were not reported. **Conclusion:** Based on the high drop-out rate in the Mfx group a comparison of both surgical procedures does not make sense. Nevertheless, in the first clinical study could be shown that the ChondroFiller liquid method is a safe and simple workable method. Although there are no experiences with this procedure in the clinical use all defects could be filled successfully. Further prospective randomized studies with higher case numbers and longer follow-up examination intervals have to be done to evaluate the importance of this new type of treatment.

**Keywords:** Cartilage repair, Cell-free collagen type I liquid, Knee Magnetic resonance Imaging, MOCART, Clinical outcome

## How to cite this article

Schneider U. Controlled, randomized multicenter study to compare compatibility and safety of ChondroFiller liquid (cell free 2-component collagen gel) with microfracturing of patients with focal cartilage defects of the knee joint. Video J Orthop Surg 2016;1:1–8.

Article ID: 100001VNP05US2016

\*\*\*\*\*

doi:10.5348/VNP05-2016-1-OA-1

Ulrich Schneider

**Affiliations:** MD, PhD, Arthro Nova Clinic GmbH, Ringsee/ Germany.

**Corresponding Author:** Prof. Dr. med. Ulrich Schneider, Arthro Nova Clinic GmbH, Wiesserstr. 103, 83707 Ringsee, Germany; Email: info@prof-schneider.eu

Received: 29 April 2016

Accepted: 11 June 2016

Published: 22 June 2016

## INTRODUCTION

The treatment of cartilage defects despite of the development of innovative procedures in the areas of cell therapy and tissue engineering remains a major challenge in the daily practice. The most often used method to treat cartilage defects is the microfracturing method. Here special plungers help make holes or microfractures in the subchondral bone layer. The microfracturing of the subchondral bone plate generates a cartilage repair by stimulating the bone marrow cells. There are relatively few studies with high evidence [1–5] although the technique is very broadly applied over several decades. Main problem of this technique is the quality of the resulting reparative tissue. There is mainly fibrous cartilage, which can shrink by and by and does not show the mechanical characteristics as the original hyaline cartilage. Nevertheless microfracturing is the gold standard on which all newly developed cartilage treatment methods are competed. That's why most of the controlled studies in the area of the cartilage surgery have chosen microfracturing as a control treatment [6–9].

In recent years, there has been increasing interest in cell-free repair approaches [10]. The use of a cell-free collagen type I gel based on rat tail collagen showed good clinical and radiological results [11, 12]. Unfortunately, this technique could be applied only in an open procedure. The modification of the preparation of this collagen makes it possible to implant this material via a pure arthroscopic approach (ChondroFiller liquid/Amedrix/Esslingen/Germany).

The aim of this study was to evaluate the efficacy of this new cell-free collagen type I matrix preparation for the repair of small to midsize chondral defects, using clinical and noninvasive MRI assessment. The hypothesis of the present study was, that the cell-free collagen type I matrix triggers chondrocyte in-growth, leading to high quality cartilage repair. The main target criterion of the study was the verification of the filling of the cartilage defect four weeks after the application.

## MATERIALS AND METHODS

The study was designed as a multicentric prospective randomized comparative study in which the ChondroFiller liquid implantation should be compared with microfracturing. Basis of the comparison was the survey of a clinical function score (IKDC) in both patient groups. The main target criterion of the study was the verification of the filling of the cartilage defect four weeks after the application.

Based on the Helsinki declaration the study was performed and was authorized by the ethics committee of the Bavarian State Chamber of Physicians. All patients gave their written permission for the performance of the study specific measures.

For the study patients between the ages of 18 and 50 should be recruited for whom within the frame of a diagnostic arthroscopy or a cartilage specific magnetic resonance examination (MRI) a local limited articular cartilage defect with a diameter of <2.5 cm was proven. Exclusion criteria included ligamentous instability, resection of (>1/3) of the meniscus, knee joint malalignment (>5°), inflammatory disease and kissing lesions.

In three centers, 23 patients were included in the study and were allocated in accordance to the defined randomization scheme into the specific study group (Table 1). All patients fulfilled the invested inclusion criteria. Out of the 13 patients who are treated with ChondroFiller liquid and documented, 11 patients had a single defect. However, patients with 2 defects, however are not located directly next to each other, were treated. Therefore, 15 defects of overall 13 patients could be evaluated.

The average age of the patients in the ChondroFiller liquid group was 47.2 years. The gender distribution showed 7 male and 6 female patients (Table 2).

The four patients of the microfracturing group were on average 36.6 years old; 2 each of them female or male.

The main criterion of the study was the verification of the implanted collagen gels after four weeks by MRI. In all 15 treated defects of the ChondroFiller group was the control MRI available at the time of the evaluation. Additionally to the MRI examination after four weeks a MRI examination after 12 months could be done in all 13 patients. At the patients of the microfracturing no MRI controls have been done.

### Cell-free collagen type-1 gel (ChondroFiller liquid)

ChondroFiller liquid is a two component collagen gel, which is isolated out of rat tail tendons. The collagen type I concentration in ChondroFiller liquid is 8 mg/mL. ChondroFiller liquid is registered as a medical device and is CE certified. The two components of the gel permit a purely arthroscopic application in a prepared cartilage defect. Before using, the implant is stored at -20°C and has to be defrosted up to 37°C in an incubator before implantation.

### Surgical Procedures

Three experienced surgeons in three centers did all the procedures. The operations were done standardized, the leg was bloodless and was in a free storage. The access to the knee joint is done standardized by the arthroscopic access. First a diagnostic arthroscopy was done with fluid to verify the medical finding and to check the indication. The cartilage defects were debrided carefully to the subchondral bone with a curette and partly with a shaver. Afterwards the defects are measured out with an arthroscopic ruler. The defect size was documented. The further procedure was performed based on the randomization to one of the two surgical procedures.

Table 1: Randomization list of recruited patients, The treatment methods are as follows: CF= ChondroFiller liquid or Mfx = microfracturing. Six patients of the Mfx-group refused the associated treatment after randomization.

| Initials | treated defects | Localisation | Defect size (cm2) | Grade | Side | Age (years) | Duration (mo) |
|----------|-----------------|--------------|-------------------|-------|------|-------------|---------------|
| GL       | 1               | MFC          | 4.8               | 4     | r    | 49          | 24            |
| EW       | 2               | Troch        | 5                 | 4     | l    | 48          | 36            |
|          |                 | lat Tib      | 2                 | 4     | l    | 48          | 36            |
| AS       | 1               | lat. Tib     | 0.8               | 4     | r    | 48          | 12            |
| JG       | 1               | MFC          | 2                 | 4     | l    | 48          | 8             |
| CS       | 2               | MFC          | 1.8               | 4     | r    | 46          | 48            |
|          |                 | Pa           | 5.7               | 4     | r    | 46          | 48            |
| UR       | 1               | MFC          | 3                 | 4     | r    | 46          | 18            |
| RUM      | 1               | MFC          | 0.8               | 4     | r    | 49          | 12            |
| RH       | 1               | lat Tib      | 0.9               | 4     | r    | 47          | 16            |
| MB       | 1               | MFC          | 1.35              | 3     | r    | 49          | 12            |
| RP       | 1               | MFC          | 1.4               | 4     | l    | 49          | 24            |
| HR       | 2               | MFC          | 0.98              | 4     | l    | 46          | 16            |
| NW       | 1               | MFC          | 2.4               | 4     | r    | 50          | 52            |
| RS       | 1               | MFC          | 6.25              | 4     | r    | 49          | 12            |

Table 2: Details of patients treated with ChondroFiller liquid; MFC= medial femoral condyle; Pa=Patella; lat Tib= lateral tibial plateau; Troch=Trochlea

| Initials | Center | Date of birth | Sex | Treatment group | Remarks        |
|----------|--------|---------------|-----|-----------------|----------------|
| TS       | 1      | 18.09.71      | M   | Mfx             | Refused random |
| DE       | 1      | 17.07.70      | M   | Mfx             | Refused random |
| GL       | 1      | 19.03.67      | M   | CF              |                |
| HB       | 2      | 06.08.68      | M   | Mfx             | Refused random |
| WD       | 2      | 30.04.72      | M   | Mfx             | Refused random |
| EW       | 2      | 09.02.65      | F   | CF              |                |
| EM       | 2      | 03.04.70      | M   | Mfx             | Refused random |
| AS       | 2      | 03.02.67      | M   | CF              |                |
| JG       | 2      | 02.11.67      | M   | CF              |                |
| GW       | 2      | 06.06.93      | M   | Mfx             |                |
| GI       | 2      | 20.12.63      | M   | Mfx             |                |
| RH       | 2      | 13.04.70      | F   | CF              |                |
| CS       | 2      | 29.07.65      | M   | CF              |                |
| BT       | 2      | 23.08.88      | F   | Mfx             | Refused random |
| CS       | 2      | 29.07.65      | M   | CF              |                |
| RU       | 3      | 17.08.63      | F   | CF              |                |
| BT       | 2      | 23.08.88      | M   | Mfx             |                |
| RM       | 2      | 21.02.64      | F   | CF              |                |
| RP       | 2      | 13.08.63      | F   | CF              |                |
| HR       | 2      | 13.04.70      | F   | CF              |                |
| NW       | 2      | 29.06.64      | M   | CF              |                |
| RS       | 2      | 02.04.65      | M   | CF              |                |
| KB       | 2      | 29.06.64      | F   | Mfx             |                |

## Microfracturing

Microfracturing (MFx) was performed according to the technique published by Steadman et al. [1, 2]. The subchondral bases of the lesions were picked by microfracture awl to a depth of 2 to 4 mm approximately 3 mm apart beginning at the periphery of the lesion. Bleeding was documented without removing the tourniquet.

## ChondroFiller liquid

The CF implantation was performed by using CO<sub>2</sub> gas medium. In the arthroscopic view, the collagen gel was filled into the defect by a cannula until the defect was filled completely. The gelification of the implant takes 3–5 minutes normally and can be estimated by the change of the color (transparent to white). The CO<sub>2</sub> feed was interrupted, the optics removed, the stab incisions stitched and a compressing dressing arranged. The surgeon renounced the insertion of drains (Video 1).

Video 1: The video shows the surgical procedure of the ChondroFiller liquid implantation in a knee joint. The access to the knee was done standardized by the typical arthroscopic access. First a diagnostic arthroscopy was done with fluid to verify the medical finding and to check the indication. The cartilage defects were debrided carefully to the subchondral bone with a curette and partly with a shaver. Afterwards the defects are measured out with an arthroscopic ruler. The defect extension was documented. The further procedure was performed by using CO<sub>2</sub> gas medium. In the arthroscopic view, the collagen gel was filled into the defect by a cannula until the defect was filled completely. The gelification of the implant takes 3–5 minutes normally and can be estimated by the change of the color (transparent to white)

[Available at: [http://www.vjorthopedicsurgery.com/archive/early-view-videos/001\\_VNP05\\_2016040001\\_OA\\_EV/001\\_VNP05\\_2016040001\\_OA\\_EV.php](http://www.vjorthopedicsurgery.com/archive/early-view-videos/001_VNP05_2016040001_OA_EV/001_VNP05_2016040001_OA_EV.php)].

## Postoperative care

The joints were immobilized postoperative for 48 h in an extended position using a brace. After 48 h the CPM-treatment (continuous passive motion) started with a motion device. This was done daily for at least 3 h over six weeks. If the issue is a femoral or tibiae defect, the CPM-treatment was done in an area of 0/0/30 during the first week. The flexion increased weekly by 30° until a full range of the extent of movement was achieved. If the issue was a patellar and/or a trochlear defect the position of the motion device and the brace was done in accordance to the arthroscopic finding. Normally, the corresponding joint partner protects the defects ideal in a bend position of 30°. Accordingly the brace was adjusted for two weeks to 30° flexion, the CPM-treatment was done between 0/30/60° during the first week. At the beginning of the second week, the extension was trained. The flexion increased by 15° weekly. The whole flexion was permitted only after six weeks.

If the issue was a femoral or tibiae defect, the patients were mobilized with a partial load bearing about 15–20 kg with underarm crutches for six weeks. After six weeks a rising intensity of the load until the full weight bearing was provided. If the issue was a patellar defect or the defect is in the area of the trochlea, with the aid of an brace the patients could put their full weight on their leg (limited flexion at 30°) immediately. After sixth month a physiotherapeutic treatment as well as a training of the joints with the bicycle was started. After at least six months the patients are allowed to perform sport-specific strains.

## Clinical evaluation

Data collection was performed preoperatively and after 3rd, 6th, and 12th months postoperatively using the subjective International Knee Documentation Committee (IKDC) score [13].

## Magnetic resonance images

The follow-up MRI examination was carried out using a standardized protocol at postoperative time-points of 4 weeks and 12 months. MRI was performed to evaluate the early postoperative adherence rate of the grafts, using a scoring system described by Marlovits et al. [14]. This system grades the transplants as completely attached, partially attached or detached. Completely attached was defined as the absence of any visible fissure/gaps between the grafts and the surrounding cartilage. In partial detachment, the graft only covered a part of the defect. The validity and the reliability of this scoring system have been proven. Further MR imaging was performed for description of the repair tissue using the MOCART (magnetic resonance observation of cartilage repair tissue) score [15]. The CF scaffold was assessed for the following nine parameters: degree and filling of the defect; integration at the border zone; structure and signal intensity of repair tissue; surface of the repair tissue, determined in two different sequences; the constitution of the subchondral bone and lamina; and the existence of adhesions and effusions. The maximum score achievable based on the evaluation of these 9 variables is 100.

All MR images were obtained with a 1.5 or a 3-Tesla MRI scanner (Siemens, Erlangen, Germany). A knee coil with a field of view of 18 cm was used with the knee positioned in extension. The following standardized sequences were recorded for coronal, sagittal and transverse slice orientations: proton density turbospin-echo fast suppression (320 9 320; thickness 3 mm; repeat time (TR) 3,000 ms; echo time (TE) 37 ms); T1 (384 9 384; thickness 3 mm; TR 411 ms; TE 13 ms); T1-volume-interpolated breath hold examination (280 9 320; thickness 1.5 mm, TR 16; TE 7); and T2 (512 9 512; thickness 3 mm; TR 460 ms; TE 15 ms). All MR images were assessed by a experienced investigator (US).



## Statistical analysis

The paired t-test was performed for the IKDC and the MOCART score to compare pre-operative and postoperative values. Data are expressed as means with standard deviations. To identify any relationships between the variables of the MOCART score and the clinical score (IKDC) at 1 year follow-up, the Pearson product moment correlation was performed. For all tests,  $p < 0.05$  was considered significant. The statistical software package SigmaStat (Version 3.5) was used for biometric analysis. Graphs were drawn using Xact 6.02 by SciLab.

## RESULTS

In the ChondroFiller liquid group overall 10 cartilage defects in the area of the medial femoral condyle, three defects in the area of the articular surface of the tibia, one defects in the area of the trochlea and one patellar defect were treated.

In the microfracturing group the defects were in the area of the medial femoral condyle (three times) and in the area of the trochlea (one time).

The mean IKDC patient values in the CF-group showed an significant increase based on the preoperative mean score from 43,3 (+/-10,4) up to 60,6 (+/-13,5) after three months and up to 72,1 (+/-13,2) after six months ( $p < 0.05$ ). This improvement remained up to one year follow-up (Figure 1).

The IKDC scores in the microfracturing group show no changes in the course after the different follow-up examination intervals (Figure 2). A statistical analyze of the data in this group is not useful because of the small number of cases.

The treated joint of all patients of the ChondroFiller group was regularly checked by MRI control examinations. The transplant in the treated defect could be evidenced at all patients in the ChondroFiller liquid group after four weeks. The first predominant edematous appearance of the transplant changed within four months significantly. Nearly all implants showed an isointense structure after these times and were hardly delimitable to the surrounding cartilage. The cases in which the defect primarily was not filled completely, a significant restructuring tendency with increasing filling of the defect area could be shown in the course (Figure 3).

This semi-quantitative evaluation of the MRI images after 4 and 52 weeks of the ChondroFiller liquid implantation by MOCART score showed a score of 65.3 (mean) at four weeks and 81.6 (mean) after one year follow-up (Figure 4). In all 15 evaluated defects, the implanted collagen gel in the defect area could be verified. All defects were filled with the implanted gel. The integration to the underlying bone and the surrounding cartilage tissue was given in all cases. The surface of the implant was smooth in most of the cases and without

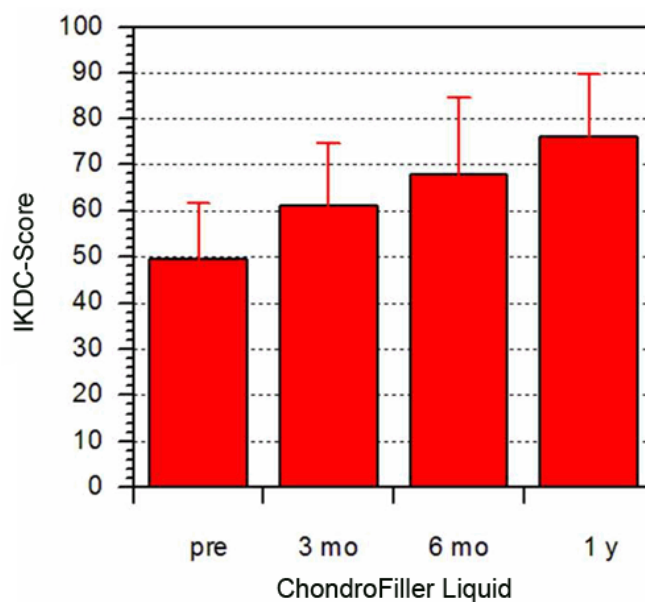


Figure 1: Description of the IKDC score of the ChondroFiller liquid group in course

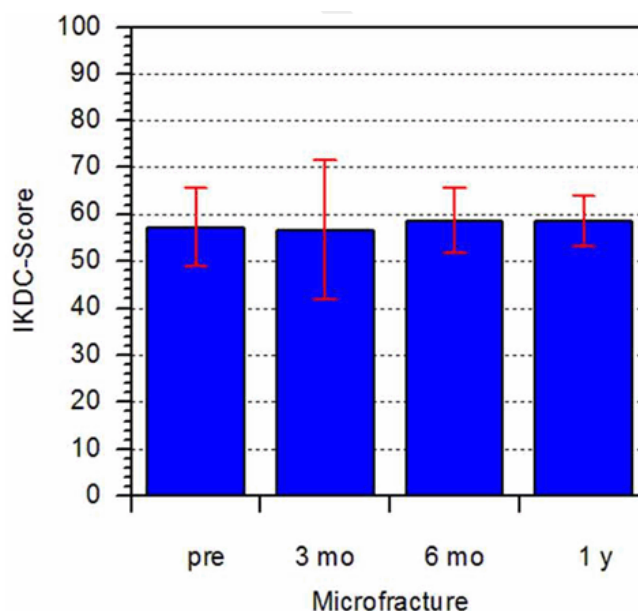


Figure 2: Description of the IKDC score in the microfracturing group in course

fissure rings representable. Based on the high liquid content a lot of implants showed a edematous appearance after four weeks and are therefore well delimitable of the surrounding cartilage tissue.

No correlation could be detected between the IKDC and the MOCART score. Adverse events in context with the performed operations could not be detected.

## DISCUSSION

The pure arthroscopic approach to implant the new collagen gel matrix is an attractive technique to restore cartilage. The operation procedure in the initial step is

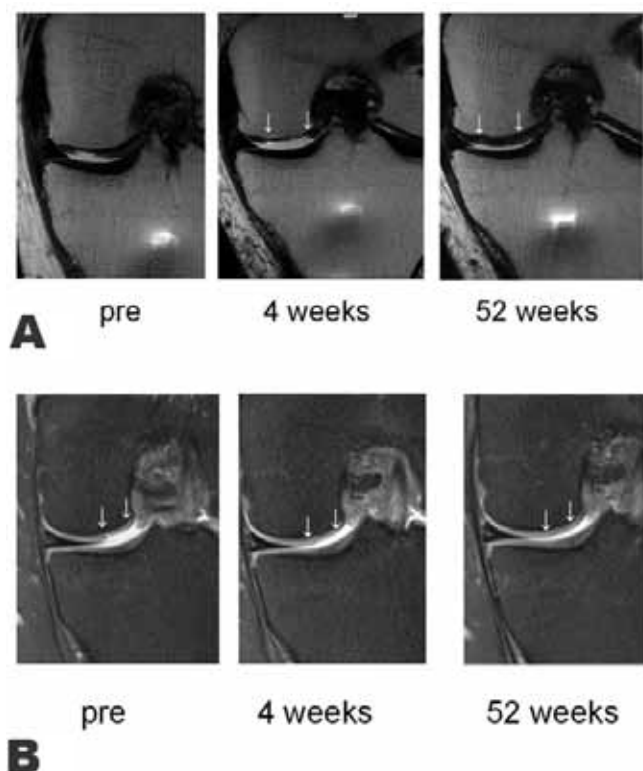


Figure 3 (A, B): MRI follow-up of patients with grade IV cartilage defect in the medial femoral condyle. The four weeks follow-up showed a complete filling of the defect. At that short time period the implant has a high water content in patient 3B and a nearly normal structure in patient 3A. After one year the implants showed an isointense structure were hardly delimitable to the adjacent cartilage.

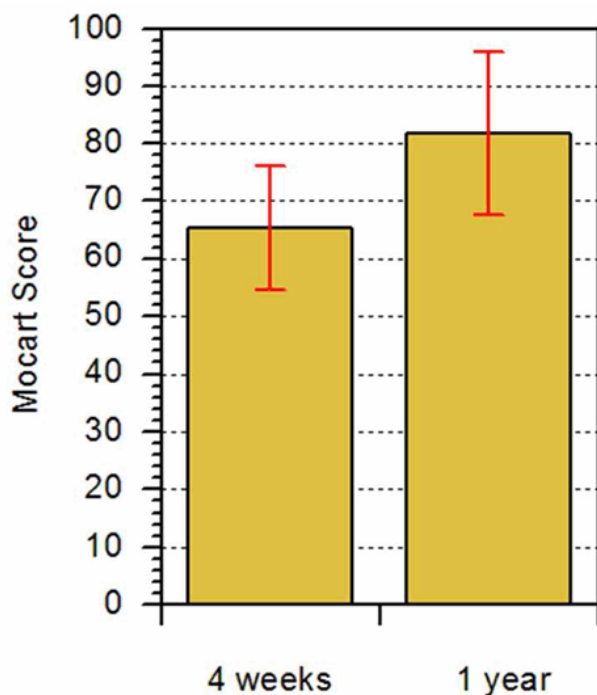


Figure 4: Evaluation of the MRI results after 4 and 48 weeks based on the MOCART scores. The results of the documented patients show exclusively good or very good fillings of the defect area (mean score at four weeks=65.3; mean score at one year=81.6).

comparable to the microfracturing technique (surgical approach, debridement of soft cartilage), however the big difference in the CF procedure is the initial complete filling of the defect with a highly biocompatible matrix. With the CF-technique we can prevent any damage of the underlying bone. Side effects as bone marrow edema, irregular structuring of the bone cartilage border, fibrocartilage conformation, shrinking of the reparation cartilage can be avoided. Bone marrow stimulation techniques show the most substantial improvements within the first two years, but the initial good results has shown to deteriorate afterwards [4]. Therefore, the follow-up of our study is too short and the Mfx control group is too small to prove the potential benefit of a high quality cartilage repair that has been shown in previous animal and human studies [11, 12, 16].

The basic principle of the CF matrix is to fill the cartilage defect with a matrix structure, providing a scaffold for chondrocytes to migrate from the perilesional tissue, enabling attachment, proliferation and extracellular matrix production. Migration of chondrocytes has been reported in collagen-based matrices in vivo and in vitro [16–19].

MRI is a well-accepted tool for the assessment of cartilage repair techniques because of good soft tissue contrast, accurate demonstration of articular cartilage and multiplanar capability [20]. The MOCART score is a well-established system for assessing articular cartilage repair tissue [14]. Welsch et al. [21] reported a mean MOCART score of 75 and 75.5 after microfracture and MACI, respectively, with a mean follow-up of 29 months. Trattinig et al. [22] reported a mean score of 73 after 12 months using the MACI procedure. In the present study, the mean MOCART score was 81.6 after 12 months.

A strong correlation between the MOCART score and the clinical outcome could not be detected. However, a direct comparison with these studies is not suitable.

The MRI evaluation showed in the present study that in the majority of the cases, there was a complete filling of the defect at 4 weeks and 12 months respectively. It is accepted that cartilage regeneration and tissue remodeling take years after implantation and cartilage remodeling is visible on MRI [14]. Therefore, studies with longer follow-up are required to gather more information about the maturation process.

Summarizing it could be stated, that based on the high drop-out rate in the Mfx group a comparison of both surgical procedures does not make sense. Nevertheless, in the first clinical study could be shown that the ChondroFiller liquid method is a safe and simple workable method. Although there are no experiences with this procedure in the clinical use all defects could be filled successfully. Further prospective randomized studies with higher case numbers and longer follow-up examination intervals have to be done to evaluate the importance of this new type of treatment.

\*\*\*\*\*

## Acknowledgements

I would like to thank the colleagues Stephan Kückelmann, Peter Diehl and Horst Müller-Kittschau for performing the surgeries and for the patient documentation.

## Author Contributions

Ulrich Schneider – Substantial contributions to conception and design, Acquisition of data, Analysis and interpretation of data, Drafting the article, Revising it critically for important intellectual content, Final approval of the version to be published

## Guarantor

The corresponding author is the guarantor of submission.

## Conflict of Interest

Author has received fees for consulting from Amedrix GmbH.

## Copyright

© 2016 Ulrich Schneider. This article is distributed under the terms of Creative Commons Attribution License which permits unrestricted use, distribution and reproduction in any medium provided the original author(s) and original publisher are properly credited. Please see the copyright policy on the journal website for more information.

## REFERENCES

1. Steadman JR, Rodkey WG, Briggs KK, Rodrigo JJ. The microfracture technic in the management of complete cartilage defects in the knee joint. *Orthopade* 1999 Jan;28(1):26–32.
2. Steadman JR, Rodkey WG, Rodrigo JJ. Microfracture: surgical technique and rehabilitation to treat chondral defects. *Clin Orthop Relat Res* 2001 Oct;(391 Suppl):S362–9.
3. Steadman JR, Briggs KK, Rodrigo JJ, et al. Outcomes of microfracture for traumatic chondral defects of the knee: average 11-year follow-up. *Arthroscopy* 2003 May-Jun;19(5):477–84.
4. Mithoefer K, Williams RJ 3rd, Warren RF, et al. The microfracture technique for the treatment of articular cartilage lesions in the knee. A prospective cohort study. *J Bone Joint Surg Am* 2005 Sep;87(9):1911–20.
5. Kreuz PC, Steinwachs MR, Erggelet C, et al. Results after microfracture of full-thickness chondral defects in different compartments in the knee. *Osteoarthritis Cartilage* 2006 Nov;14(11):1119–25.
6. Knutsen G, Engebretsen L, Ludvigsen TC, et al. Autologous chondrocyte implantation compared with microfracture in the knee. A randomized trial. *J Bone Joint Surg Am* 2004 Mar;86-A(3):455–64.
7. Saris DB, Vanlauwe J, Victor J, et al. Characterized chondrocyte implantation results in better structural repair when treating symptomatic cartilage defects of the knee in a randomized controlled trial versus microfracture. *Am J Sports Med* 2008 Feb;36(2):235–46.
8. Basad E, Ishaque B, Bachmann G, Stürz H, Steinmeyer J. Matrix-induced autologous chondrocyte implantation versus microfracture in the treatment of cartilage defects of the knee: a 2-year randomised study. *Knee Surg Sports Traumatol Arthrosc* 2010 Apr;18(4):519–27.
9. Anders S, Volz M, Frick H, Gellissen J. A Randomized, Controlled Trial Comparing Autologous Matrix-Induced Chondrogenesis (AMIC®) to Microfracture: Analysis of 1- and 2-Year Follow-Up Data of 2 Centers. *Open Orthop J* 2013 May 3;7:133–43.
10. Schüttler KF, Efe T. Tissue regeneration in orthopedic surgery - do we need cells? *Technol Health Care* 2015;23(4):403–9.
11. Efe T, Theisen C, Fuchs-Winkelmann S, et al. Cell-free collagen type I matrix for repair of cartilage defects-clinical and magnetic resonance imaging results. *Knee Surg Sports Traumatol Arthrosc* 2012 Oct;20(10):1915–22.
12. Roessler PP, Pfister B, Gesslein M, et al. Short-term follow up after implantation of a cell-free collagen type I matrix for the treatment of large cartilage defects of the knee. *Int Orthop* 2015 Dec;39(12):2473–9.
13. Irrgang JJ, Anderson AF, Boland AL, et al. Development and validation of the international knee documentation committee subjective knee form. *Am J Sports Med* 2001 Sep-Oct;29(5):600–13.
14. Marlovits S, Singer P, Zeller P, Mandl I, Haller J, Trattnig S. Magnetic resonance observation of cartilage repair tissue (MOCART) for the evaluation of autologous chondrocyte transplantation: determination of interobserver variability and correlation to clinical outcome after 2 years. *Eur J Radiol* 2006 Jan;57(1):16–23.
15. Marlovits S, Striessnig G, Kutscha-Lissberg F, et al. Early postoperative adherence of matrix-induced autologous chondrocyte implantation for the treatment of full-thickness cartilage defects of the femoral condyle. *Knee Surg Sports Traumatol Arthrosc* 2005 Sep;13(6):451–7.
16. Gavenis K, Schmidt-Rohlfing B, Andereya S, Mumme T, Schneider U, Mueller-Rath R. A cell-free collagen type I device for the treatment of focal cartilage defects. *Artif Organs* 2010 Jan;34(1):79–83.
17. Schneider U, Schmidt-Rohlfing B, Gavenis K, Maus U, Mueller-Rath R, Andereya S. A comparative study of 3 different cartilage repair techniques. *Knee Surg Sports Traumatol Arthrosc* 2011 Dec;19(12):2145–52.
18. Morales TI. Chondrocyte moves: clever strategies? *Osteoarthritis Cartilage* 2007 Aug;15(8):861–71.
19. Schüttler KF, Struwer J, Rominger MB, Rexin P, Efe T. Repair of a chondral defect using a cell free scaffold in a young patient--a case report of successful scaffold transformation and colonisation. *BMC Surg* 2013 Apr 16;13:11.
20. Alparslan L, Minas T, Winalski CS. Magnetic resonance imaging of autologous chondrocyte implantation. *Semin Ultrasound CT MR* 2001 Aug;22(4):341–51.
21. Welsch GH, Trattnig S, Domayer S, Marlovits S, White LM, Mamisch TC. Multimodal approach in the use of clinical scoring, morphological MRI and biochemical T2-mapping and diffusion-weighted

imaging in their ability to assess differences between cartilage repair tissue after microfracture therapy and matrix-associated autologous chondrocyte transplantation: a pilot study. *Osteoarthritis Cartilage* 2009 Sep;17(9):1219–27.

22. Trattig S, Ba-Ssalamah A, Pinker K, Plank C, Vecsei V, Marlovits S. Matrix-based autologous chondrocyte

implantation for cartilage repair: noninvasive monitoring by high-resolution magnetic resonance imaging. *Magn Reson Imaging* 2005 Sep;23(7):779–87.

Access full text article on  
other devices



Access PDF of article on  
other devices

